CASE REPORT

# Interlocked Twins: A Case Report

**Sudhaa Sharma, Amandeep Anand, Reema Khajuria**

**Abstract**
Interlocking of twins is an exceedingly rare and potentially hazardous obstetric complication.we report a rare condition of an unbooked case of interlocked twins that attended labor room in advanced second stage of labour.

**Key Words**
Interlocked Twins, Caesarean Section, Perinatal Death

## Introduction

Interlocking of twins is an exceedingly rare and potentially hazardous obstetric complication. It usually occurs when the after coming head of the first breech is locked with the head of the second fetus with cepalic presentation. It occurs in approximately 1 in 90,000 deliveries or 1 in 1,000 twin births.(1) Herein, we report the rare condition of an unbooked case of interlocked twins that attended our labor room in advanced second stage of labour.

## Case Report

An unbooked Rh-negative primigravida aged 23 years was admitted in the labor ward of SMGS Hospital, Government Medical College, Jammu as a case of amenorrhea 8 months with labor pains. As per her last menstrual period her gestational age was 35 weeks. She looked apparently healthy and her general physical examination revealed mild pallor, blood pressure of 120/70 mmHg and no peripheral edema. She appeared to be in advanced second stage of labor. Per abdomen examination revealed over distended uterus. On account of strong uterine contractions there was consequent difficulty in identifying fetal parts and fetal heart sounds were not audible. Pelvic examination showed fully dilated os, absent membranes and breech at +1 station. Within minutes of unsatisfactory examination, buttocks were seen to appear at vulva and the patient was hastily positioned for a breech delivery. An unassisted breech delivery was then partially accomplished with no difficulty including the delivery of arms. The incompletely delivered breech was allowed to hang for full two minutes to maintain flexion and encourage descent to accomplish delivery by Burns-Marshall technique. Then feet were held and it was tried to take trunk upwards covering arc of a circle to complete delivery of the head but it could not be accomplished. A hand was then passed into the vagina with the object of reaching the mouth in order to complete delivery of head by the Mauriceau-Smellie-Veit method. The internal hand discovered a second head engaged in the pelvis just below the ischial spine level and in the hollow of the sacrum.(*Fig-1*) The neck of the undelivered breech was elongated and pushed up anteriorly against the symphysis pubis. The head of the undelivered breech was above the ischial spine level. Suspecting interlocking of twins, the patient was immediately shifted to operation theatre and general anesthesia was given. Under general anesthesia, the diagnosis of locked twins was confirmed. The cervix was fully dilated and fully effaced. The mid cavity and pelvic outlet were adequate in size. An attempt was made to disimpact the second twin's head, but the locking was too firm. No cord pulsations could be felt in the cord of the first fetus nor could any signs of life be detected. Fetal heart sounds of the second twin were not heard after careful and systematic listening and it was assumed that it too had died. As the locking was very tight and the second baby's fetal heart was absent, decision for destructive operation was taken. An indwelling Foley's catheter was put in. Decapitation of first twin was done, brain matter was churned out and collapsed head was held by Alli's forceps followed by perforation and decompression of second head. Collapsed head held with Allis forceps was pushed up, 2nd twin was delivered first,

**From the Department of Obst and Gyane, Govt Medical College, Jammu (J&K)- India**
**Correspondence to :** Dr Sudhaa Sharma, Associate Professor, Deptt. of Obstetrics & Gynecology, Govt. Medical College & SMGS Hospital, Jammu (J&K)

*Fig.1 Showing Arrest of After Coming Head of First Twin*

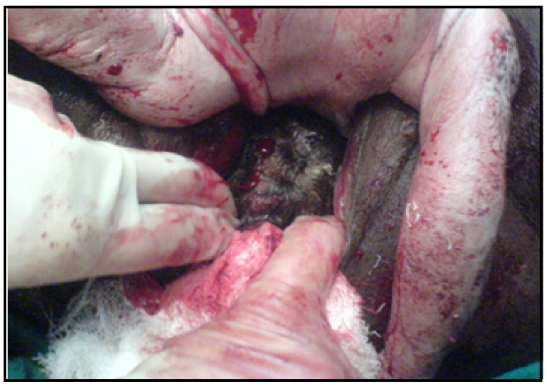

followed by delivery of collapsed head of the first twin. The third stage of labor was uncomplicated. There was single placenta with two cords and a single amniotic sac. Examination of twins after delivery showed them to be mature and well developed. Both were females weighing 1.5 and 1.7 kg respectively. These weights did not include that of brain tissue lost after perforation. Patient received 300 microgram of Anti-D immunoglobulin post delivery. The puerperium was uneventful and patient was discharged from hospital on 14th post partum day after removal of catheter. The patient was followed up for 6 weeks postnataly and was found to be doing well with no complication.

**Discussion**

Twin interlocking is an exceedingly rare complication that has a high fetal mortality and morbidity rate. Twin locking denotes the condition where the inferior aspect of each twin's chin is apposed to each other in a vertical axis. This occurs during vaginal delivery when the co-twins lie vertically with the first twin presenting as a breech and the second twin presenting as vertex. In recent years the trend has been for greater use of cesarean sections and ultrasound in managing twin deliveries.(2) It rarely happens in current obstetric practice, since the presentation of both the twins can be readily determined by ultrasound examinations and cesarean section is routinely performed if the presenting twin is in a breech position. The interlocking may occur, first, above the pelvic inlet, resulting in failure of descent of the presenting twin or, second, at or below the inlet if the presenting twin has been partly delivered. There appear to be several predisposing factors in the etiology of locked twins. The predisposing factors are small fetuses, an unduly roomy pelvis, premature rupture of membranes leading to oligohydramnios, mono-amniotic twins, and hypertonicity of the uterus. In cases of interlocked twins in which vaginal delivery is attempted, loss of first twin is common.(3) The perinatal mortality of the interlocking twins is about 50% with the presenting twin accounting for 80% of the perinatal deaths. (2) Treatment can hardly be premeditated. Locking is usually diagnosed only during the delivery and very seldom during labor. Our experience and the others reporting such cases indicate that early cesarean sections can prevent such a disastrous outcome. Suspicion of a collision or interlocking syndrome should be aroused in any patient carrying twins with first twin in breech/transverse position. Since these entanglements are a complication of the late second stage of labour, they are not easily predicted and hence American College of Obstetricians and Gynaecologists consider an abdominal delivery as the preferred mode for this presentation. (2) Abdominal delivery should be accomplished before descent of the presenting twin. (3) In cases, where interlocking is detected during advanced labour, each case has to be managed individually. Disengagement should be attempted first, preferably under deep anesthesia. If disengagement fails, decapitation of the first twin becomes essential, though caesarean section could be carried out, especially if fetus is alive.(4) A successful outcome in locked twins has also been found after applying the Zavanelli maneuver.(5) Also in another case report from Johannesburg, South Africa hexoprenaline sulfate, a beta-sympathomimetic drug was used to relax the uterus to disimpact fetal heads and locked twins were delivered vaginally successfully.(6)

**Conclusion**

Timely detection of potential cases especially twins with first breech or transverse and carrying out caesarian deliveries in them can prevent mortality in this rare entity. The management of interlocked twins must be individualized. Our case being unbooked and presenting late in second stage of labor was unfortunate as none of the twins could be saved.

**References**


1. Deiry SK. Two Cases of Locked Twins. *Br Med J* 1960 ; 1(5180): 1174-1177.
2. Kurzel RB. Twin entanglement revisited. *Twin Res* 1998 ;1(3):138-41.
3. Wolk BM, Sindler MJ, Durkan JP. Collision and interlocking of twins. *South Med J* 1977; 70(3):364-65
4. T Borah, A Das. Locked Twins: A Rarity. *Ann Med Health Sci Res* 2012 ; 2(2): 204-05.
5. Saad FA, Sharara HA. Locked twins: a successful outcome after applying the Zavanelli manoeuvre. *J Obstet Gynaecol* 1997;17(4):366-67.
6. Sevitz H, Merrell DA. The use of a beta-sympathomimetic drug in locked twins. *BJOG Int J Obst & Gynaecol* 1981;88: 76-77.